

Clinical and radiological long-term outcome after posterior cruciate ligament reconstruction and popliteus bypass surgery- what could we expect?

Adler T¹, Friederich NF¹, Amsler F², Müller W¹, Hirschmann MT¹

¹Department of Orthopaedic Surgery and Traumatology, Kantonsspital Baselland, Bruderholz, Switzerland

²Amsler Consulting, Basel, Switzerland

Background

Injuries of the posterior cruciate ligament (PCL) are common with an incidence up to 20% of all knee injuries. They are often combined with injuries of the posterolateral corner of the knee, resulting in a severe instability.

Missed combined injuries inevitably lead to development of osteoarthritis. During the last decades many techniques have been developed in order to reconstruct the posterolateral corner of the knee. One technique is the popliteus bypass according to Mueller, which was developed by Professor Mueller being the former head of the department of orthopaedic surgery of the Kantonsspital Bruderholz.

The primary purpose of our study was to analyze the long-term outcome of patients treated for combined PCL and posterolateral corner injuries by PCL reconstruction and popliteus bypass according to Mueller or refixation of the popliteus tendon.

Materials and methods

16 patients (male:female=10:6, mean age at surgery 32±14 years) treated by combined PCL reconstruction and popliteus bypass according to Mueller (n=7) or a refixation of the popliteus tendon (n=9). The patients were evaluated with a mean follow-up of 24±3 years using IKDC2000, the SF36, Lysholm and Tegner score and KOOS score. Anterior and posterior KT-1000 arthrometer measurements were performed. Bilateral anterior-posterior stress radiographs (in 30° and 90° flexion) were performed as well as varus stress radiographs. The degree of osteoarthritis was assessed as Kellgren Lawrence Score. Pearson correlations of predictive factors for worse outcome were performed. The level of statistical significance was p<0.05.

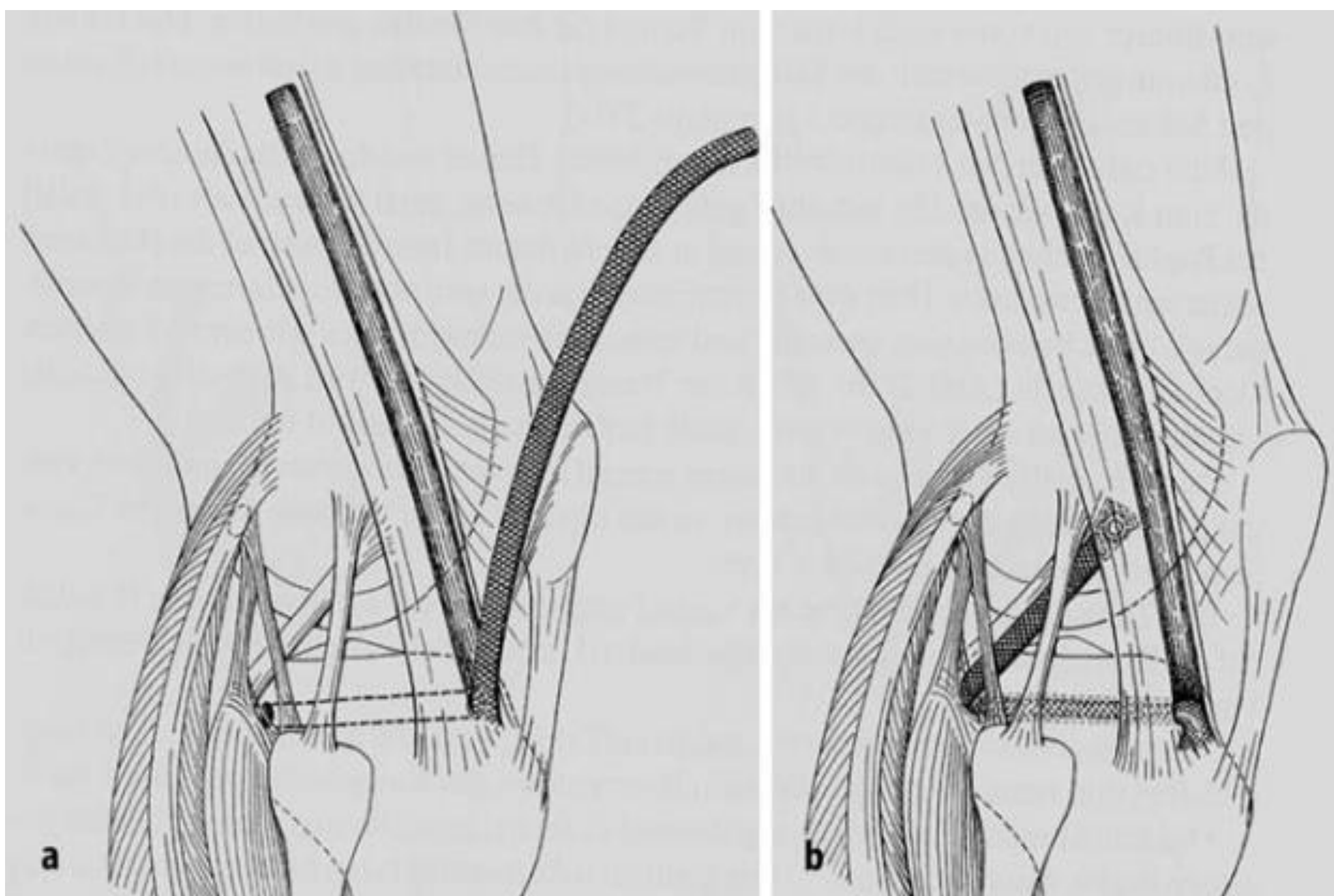


Figure 1:

The technique of the popliteus bypass according to Mueller. A flap of the iliotibial tract is pulled dorsally through a tibial drill hole. Then it is fixed at the anatomical femoral attachment of the popliteus tendon. In addition, the bypass is fixed parallel to the residual popliteus tendon at the lateral capsule of the knee joint. Alternatively, a flap of the biceps tendon can be used as the transplant.

With kind permission from Springer Science+Business Media: "Das Knie. Form, Funktion und ligamentäre Wiederherstellungschirurgie. Springer Berlin Heidelberg 1982/Edition 1. Morscher E, Muspach R, Müller W. Figure 271a,b, page 27

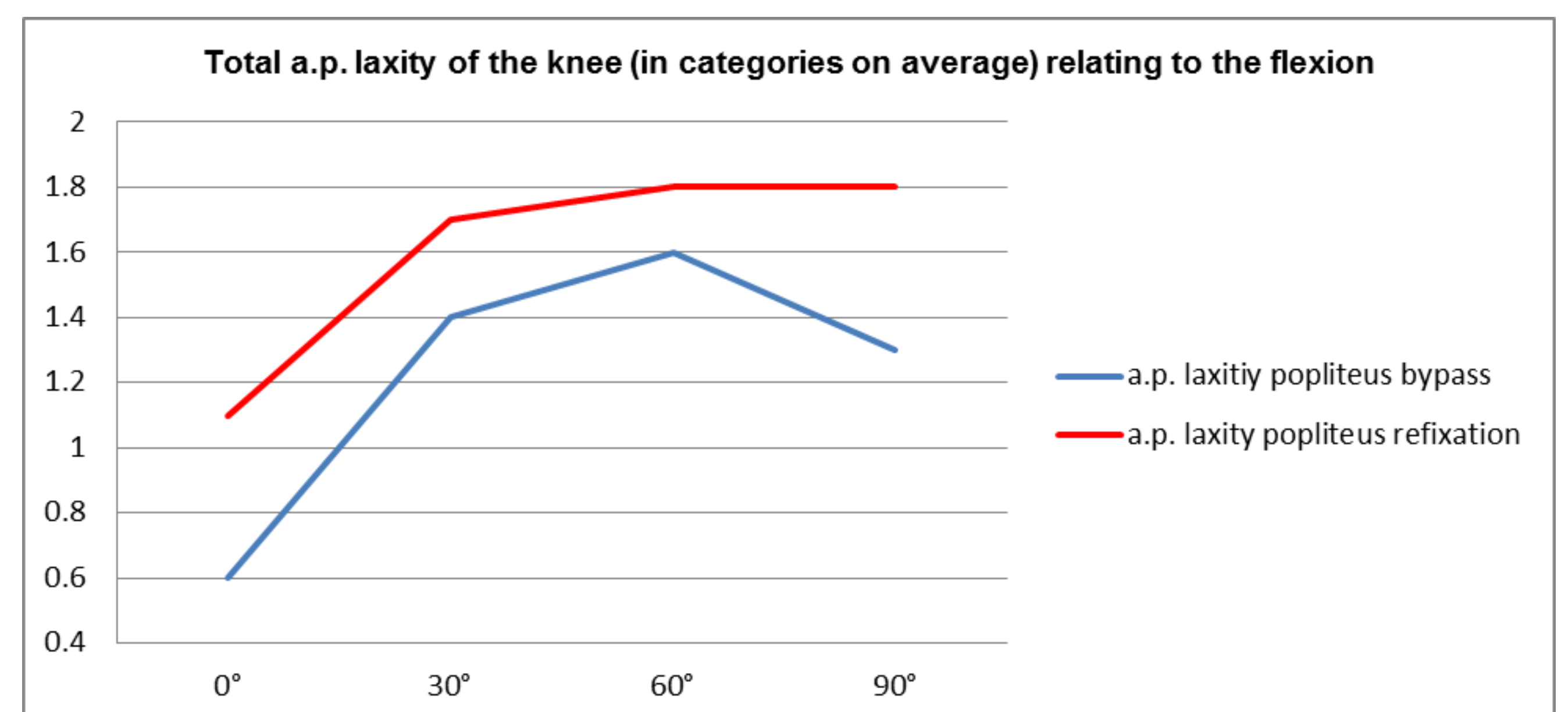


Figure 2:

The total anterior-posterior laxity of the knee manually tested in categories. Category 0: 0-2mm laxity, category 1: 3-5mm, category 2: 6-10mm, category 3: more than 10mm.

Results

The total IKDC2000 was B (nearly normal) in 5 (31%), C (abnormal) in 7 (44%) and D (severely abnormal) in 4 (25%) of patients. The mean total SF-36 health survey was 79±20, the Lysholm score 68±22, the KOOS-symptoms 40±13, KOOS-pain 26±24, KOOS-activity 18±18, KOOS-sport 51±32, KOOS-LQ 44±26. The Tegner score decreased from preinjury (7, 4-10) to (4, 2-10) at follow-up.

The side to side differences of anterior KT-1000 arthrometer measurements 134N were 5±5mm. The side to side difference of bilateral posterior stress radiographs in 30° was 4±5 mm and 6±3 mm in 90° flexion. The side to side difference of bilateral varus stress radiographs was 3±2 mm.

The Kellgren Lawrence score showed minimal osteoarthritis in 7 (44%), moderate osteoarthritis in 7 (44%), and severe osteoarthritis in 1 patient (12%). One of the patients had undergone a total knee replacement.

The knees with the popliteus bypass showed a less laxity on average while testing manually than the knees with a performed popliteus refixation. In addition, a decrease of laxity in 90° of knee flexion in the popliteus bypass group was recognized.

Conclusion

The challenging group of patients with combined PCL injury and posterolateral corner injuries treated by PCL reconstruction and popliteus bypass according to Mueller et al. or popliteus refixation showed only moderate clinical and radiological outcome, even when the age of the patients at surgery and the long-term follow-up is acknowledged. The type of posterolateral corner reconstruction using these two methods did not show any statistical difference in outcomes.

A trend was recognized that the popliteus bypass leads to less laxity than the refixation. However, a statistical difference could not be found.

References

- Müller W (1982): Das Knie. Form, Funktion und ligamentäre Wiederherstellungschirurgie. Springer. Berlin Heidelberg New York
- Hoffman F (2004): Posterior knee instability. Orthopäde 33(1):87-104
- LaPrade RF (2006): Posterolateral knee injuries. Anatomy, evaluation, and treatment. Thieme New York Stuttgart
- Strobel MJ, Weiler A (2008): Hinteres Kreuzband. Anatomie, Diagnostik und Operationstechnik. Endo Press Tuttlingen